

Primary Non Hodgkin Lymphoma Cervix –A Rare Case Report

Nirmal Arasu*, Mridul Anand**, Ankita Parikh***, Sonal Patel Shah***

Abstract :

Lymphoma of uterine cervix is very rare. Here we reporting a case of Diffuse large B cell lymphoma treated at Gujarat cancer research institute in 2017. We collected the data from patient's case file. The patient had received 6 cycles of CHOP [cyclophosphamide, doxorubicin, vincristine, prednisolone] regimen chemotherapy. And the patient showed good response. Here by concluding the combination of chemotherapy and radiotherapy is very much effective in management of lymphoma of uterine cervix.

Key Words : Lymphoma, Radiotherapy, Uterine cervix

Introduction :

Primary Non-Hodgkin lymphoma (NHL) affects extra nodal sites in one third of cases. Gastrointestinal tract and skin are the most commonly affected extra nodal sites. Only 0.5% of extra nodal lymphoma in human are likely to originate in female genital tract, most commonly ovary. Primary Non-Hodgkin lymphoma of uterine cervix is rarely reported in literature. Cervix was involved in 1 out of 730 cases of NHL and 1 out of 175 cases of extra nodal lymphoma, according to one study.⁽¹⁾ It usually high grade B cell lymphoma.⁽²⁾ Abnormal uterine bleeding is a most common presenting symptom.⁽³⁾ Persistent dyskaryosis on cervical cytology, abnormal pap smear, fever, abdominal pain and bilateral hydronephrosis are other manifestations. We report a case of NHL cervix and provide a review of literature.

Case presentation:

A 40 year old female presented with bleeding and

whitish discharge per vaginum, and lower abdominal pain since duration of 2 months. She had no history of fever, weight loss or night sweats. Physical examination revealed pallor without lymphadenopathy or organomegaly. Complete blood and count and renal function tests are normal. Serological markers are negative. On pelvic examination hard, lobulated mass arising from cervix, involving upper one third of anterior and right lateral vaginal wall. Left lateral and posterior vaginal walls are free. Per rectal examination revealed hard central bulge 4 X 4 cm, right parametrium 2 fingers short and left parametrium 1 finger short of lateral pelvic wall. Ultrasound abdomen and pelvis suggestive of 5 X 4.9 X 6.9cm mass lesion over cervix extending to lower body of uterus and upper vagina and suspicious involvement of left parametrium. Lesion abuts base of urinary bladder and anterior rectal wall with preserved fat plane. Cervical biopsy suggestive of poorly differentiated carcinoma or NHL or melanoma. Immuno-histochemistry was positive for LCA and vimentin, negative for CK-7 and CD20. The diagnosis of large cell lymphoma B type was made and CHOP regimen and radiotherapy was suggested. Patient received 6 cycles of CHOP regimen.^(2, 4-7) Post chemotherapy computed tomography was suggestive of bulky

* Resident,
** Junior Lecturer,
*** Associate Professor, Department of Radiotherapy,
Gujarat Cancer and Research Institute, Ahmedabad, Gujarat

Correspondence : Dr. Nirmal Arasu

E-mail : E-mail: arasunirmal14@gmail.com

cervix. Pelvic radiotherapy 50Gy in 25 fractions by conventional external beam radiotherapy was planned and delivered on linear accelerator. She completed treatment in December 2016. During her treatment she developed grade 1 skin reaction.

Fig. 1: CT abdomen and pelvis showing lymphoma of cervix

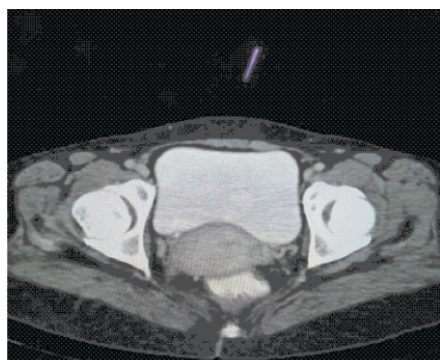
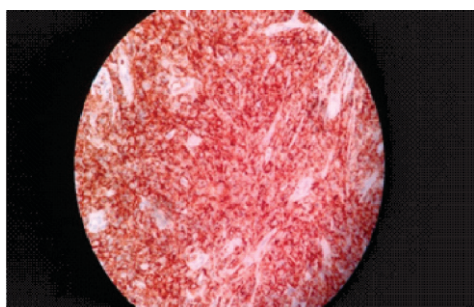

Fig. 2: Slide showing LCA positive



Discussion:

Primary Non Hodgkin lymphoma of uterine cervix is rare. Common presenting symptom is vaginal bleeding. Vaginal discharge, fever, abdominal pain and hydronephrosis are other manifestation. The differential diagnosis of cervical lymphoma includes sarcoma, neuroendocrine tumors, malignant mixed mullerian tumor, melanoma, extra-osseous ewing sarcoma and chronic cervicitis. These tumors are managed with chemotherapy, radiotherapy and surgery,⁽⁴⁻⁶⁾ alone or in combination. Chinese authors prefer combination of surgery and chemotherapy

. Holweg et al. and many other researches recommend radiation after surgical staging.⁽⁸⁾ ⁹⁾Most effective treatment recommended by most authors is combination of systemic chemotherapy and irradiation.⁽¹⁰⁻¹²⁾ We should consider this treatment for primary non Hodgkin lymphoma of uterine cervix.

Conclusion:

Non-hodgkin lymphoma of uterine cervix is a very rare tumor. It is usually high grade B cell lymphoma. Deep biopsy is required for diagnosis. Combination of chemotherapy and radiotherapy is the most effective treatment with early good outcome.

References:

1. Chorlton I., Karnei R. F., Jr., King F. M., Norris H. J. Primary malignant reticuloendothelial disease involving the vagina, cervix, and corpus uteri. *Obstetrics & Gynecology*. 1974;44(5):735–748. [PubMed].
2. Garavaglia E., Taccagni G., Montoli S., et al. Primary stage I–III non-Hodgkin’s lymphoma of uterine cervix and upper vagina: evidence for a conservative approach in a study on three patients. *Gynecologic Oncology*. 2005;97(1):214–218. doi: 10.1016/j.ygyno.2004.07.065. [PubMed] [Cross Ref].
3. Vang R., Jeffrey Medeiros L., Ha C. S., Deavers M. Non-Hodgkin’s lymphomas involving the uterus: a clinicopathologic analysis of 26 cases. *Modern Pathology*. 2000;13(1):19–28. doi: 10.1038/modpathol.3880005. [PubMed] [Cross Ref].
4. Chan J. K., Loizzi V., Magistris A., et al. Clinicopathologic features of six cases of primary cervical lymphoma. *American Journal of Obstetrics and Gynecology*. 2005;193(3):866–872. doi: 10.1016/j.ajog.2005.04.044. [PubMed] [Cross Ref].
5. Anagnostopoulos A., Mouzakiti N., Ruthven S., Herod J., Kotsyfakis M. Primary cervical and

- uterine corpus lymphoma; a case report and literature review. *International Journal of Clinical and Experimental Medicine*. 2013;6(4):298–306. [PMC free article] [PubMed].
6. Vasudev D. S., Kaler A. K. Case report: non-Hodgkin's lymphoma of the uterine cervix. *Online Journal of Health and Allied Sciences*. 2012;11(1, article 13).
 7. Heredia F., Bravo M., Pierotic M., Majlis A., Carmona L. Neoadjuvant combined chemotherapy followed by external whole pelvic irradiation in two cases of primary extranodal non-Hodgkin's lymphoma of the uterine cervix. *Gynecologic Oncology*. 2005;97(1):285–287. doi: 10.1016/j.ygyno.2004.12.018.[PubMed] [Cross Ref].
 8. Sun M, Cao J, Zhang G. Ten case report on primary cervical lymphoma. *Abstract. Chung Liu TsaChih* 1997;19(3):206-8.
 9. Holweg M, Kopp A, Stegner HE, Loning T, Jonat W. Primary lymphoma of the cervix uteri - 2 case reports. *Source GeburtshilfeFrauenheilkd* 1995;55:171-2.
 10. Stroh EL, Besa PC, Cox JD, et al. Treatment of patients with lymphomas of uterus or cervix with combination chemotherapy and radiation therapy. *Cancer*. 1995;75:2392– 2399. doi: 10.1002/1097-0142(19950501)75:9<2392::AID-CNCR2820750932>3.0.CO;2-Y. [PubMed] [Cross Ref].
 11. Amichetti M, Chiappe E, Mussari S, et al. Primary non-Hodgkin's lymphoma of the female genital tract. *Oncol Rep*. 1999;6:651–654. [PubMed].
 12. Muntz HG, Ferry JA, Flynn D, et al. Stage IE primary malignant lymphomas of the uterine cervix. *Cancer*. 1991;68:2023–2032. doi: 10.1002/1097-0142(19911101)68:9<2023::AID-CNCR2820680930> 3.0.CO;2-V. [PubMed] [Cross Ref].